

The effect of hyperbaric oxygen breathing on the visual field in glaucoma

Lovre Bojić¹, Goran Račić², Stracimir Gošović³
and Hasan Kovačević³

Department of Ophthalmology¹, Department of ENT² of New Hospital, and
Department of Underwater and Hyperbaric Medicine³ of Naval Medical Institute, Split, Croatia

Abstract. Following the hypothesis that chronic ischemia is the main cause of functional deficiency in glaucoma, a double blind clinical experiment was carried out to study the effect of hyperbaric oxygenation in 51 glaucoma subjects, of which 31 were in the experimental group and 20 in the control group. In the experimental group there was a significant improvement of visual fields ($p < 0.05$), whereas there was no change in the subjects in the control group. Hyperbaric oxygen did not have any influence on intraocular pressure. The achieved visual field improvements remained stable for 3 months ($p < 0.05$), except for I₃ and I₄ isopters of the left eye and I₄ isopter of the right eye, while they were considerably reduced after 6 months ($p > 0.05$).

Key words: glaucoma - hyperbaric oxygenation.

Primary open-angle glaucoma is a multifactorial disease of a chronic progressive nature. The prevention of glaucoma depends on a rational therapy and recognition of early changes in the optic nerve head, the retinal nerve fiber layer and visual field (Tuulonen et al. 1991). The theories concerning pathogenesis of a reduced visual field are controversial (Anderson 1977). In addition to the direct action of the elevated intraocular pressure (IOP) on the visual field, deterioration of the visual field may be caused by blocking of axonic transport in the extensions of the optic nerve (Radius 1987; Quigley et al. 1981). A vascular theory of ischemia also is widely accepted (Hayreh et al. 1970; Phelps 1972; Duke-Elder et al. 1976).

The question remains, however, if an elevated IOP as a primary mechanical effect blocks axoplasmic transport or not, or is a secondary effect as the consequences of ischemia of the vascular system, i.e. in the feeding nutritive capillaries (Anderson 1977).

Despite the numerous and often contradictory opinions, it is broadly accepted that ischemia is one of the basic causes of glaucoma lesions due to a vascular nutritive deficiency of the peripapillary choroid and capillaries of the optic nerve (Hayreh et al. 1970; Phelps 1972; Duke-Elder et al. 1976).

A therapeutic ideal would be to obtain reversibility of optic nerve head and visual field changes in glaucoma. The literature on medical treatment confirms the clinical impression that in a number of patients the disease progresses despite so-called controlled IOP (Greve 1989).

Reducing IOP to a statistically 'normal' pressure level may not be sufficient and the aim of the treatment must be to preserve the visual field.

Hyperbaric oxygenation (HBO) has been used for many years (Cramer 1985). Recent advances in the knowledge of the effects of HBO on retinal anoxia gave rise to a new interest in the possibility of using it as a therapeutic treatment for ischemic conditions of the retina (Jain 1990).

The many findings which indicate that ischemia is one of the leading factors in the etiology of glaucoma, inspired us to conduct a controlled clinical research project on the effects of HBO in glaucoma.

Table 1.

The intraocular pressure was not changed in the experimental or control group without regard do use of hyperbaric oxygenation.

Subjects	Before HBO		After HBO	
	Left eye	Right eye	Left eye	Right eye
Experimental group n=31	17.2 ± 0.2	17.6 ± 0.3	17.2 ± 0.2	17.2 ± 0.3
Control group n=20	17.1 ± 0.5	16.6 ± 0.5	17.2 ± 0.5	16.4 ± 0.6

Material and Methods

The study was conducted as a double blind clinical test on 51 Caucasian subject aged 45 to 65 (mean age 56.9 ± SD 6.3 years). Sampling was random from two groups: one experimental group with 31 patients and a control group with 20 patients. All patients had open-angle glaucoma and the IOP was regulated with medication.

Before the start of the study, all subjects had an ophthalmological examination and a standard clinical evaluation by which any contraindications for exposure to high pressure atmosphere and breathing hyperbaric oxygen were eliminated. All subjects were told the objective of the study and had signed an agreement to participate. Prior to commencing treatment, the visual field of all subjects was determined using a method of kinetic perimetry by Goldmann (type Marc 2000). Attention was paid to blind spot and isopters. The ob-

tained areas of the visual fields were digitized on a Digital PDP-11/75 computer. Testing was conducted on the Naval Medical Institute in Split, Croatia, using a large walk-in recompression chamber.

The subjects from both groups were exposed in the chamber to a pressure of 2.0 bars once each day for 90 min, five times a week, for a total of 30 sessions. During each session in the chamber, the subjects in the experimental group breathed oxygen for 45 min, then air for 5 min and then again oxygen for 40 min. Oxygen was supplied from a subsystem for breathing oxygen type SAA-1, with an oxygen external dumping system of the exhausted gases rich with oxygen.

The control group breathed air with 10.5% O₂, also under pressure of 2.0 bars. The 5 min interruption was done to avoid toxic oxygen action on the experimental group. In order to make the test

Table 2.

By HBO significantly improved visual field remained stable for 3 months except i.e. I₃ and I₄.

		Blind spot	Isopters			
			I ₁	I ₂	I ₃	I ₄
Surface in cm ² before HBO	l.e.	0.68 ± 0.06	4.1 ± 0.7	27.8 ± 3.2	73.8 ± 5.2	121.2 ± 5.4
	r.e.	0.83 ± 0.11	4.1 ± 0.7	30.8 ± 2.8	77.8 ± 3.8	124.8 ± 3.9
Surface in cm ² after HBO	l.e.	0.51 ± 0.03*	8.0 ± 0.9*	37.8 ± 3.1*	87.0 ± 4.0*	134.1 ± 3.6*
	r.e.	0.52 ± 0.09*	8.4 ± 0.8*	40.9 ± 2.8*	89.3 ± 3.8*	135.8 ± 3.4*
Surface in cm ² 3 months later	l.e.	0.58 ± 0.04*	7.6 ± 0.9*	36.8 ± 3.3*	78.8 ± 4.9**	128.4 ± 5.1**
	r.e.	0.53 ± 0.09*	7.9 ± 0.7*	38.7 ± 2.8*	88.7 ± 3.6*	134.5 ± 3.4**
Surface in cm ² 6 months later	l.e.	0.6 ± 0.04**	5.5 ± 0.6**	32.7 ± 3.4**	74.2 ± 4.1**	124.8 ± 3.5**
	r.e.	0.63 ± 0.1**	5.7 ± 0.6**	31.2 ± 3.1**	80.9 ± 3.7**	123.8 ± 3.0**

* p < 0.05; ** p > 0.05; l.e. = left eye; r.e. = right eye.

Table 3.

By HBO significantly improved visual field remained stable for 3 months except l.e. I₃ and I₄. Results of Student's *t*-test of the experimental group.

		Blind spot	Isopters			
			I ₁	I ₂	I ₃	I ₄
After HBO	l.e.	t = 2.3 p = 0.02	t = 3.2 p = 0.01	t = 2.2 p = 0.03	t = 1.9 p = 0.05	t = 2.0 p = 0.04
	r.e.	t = 2.0 p = 0.04	t = 4.1 p < 0.01	t = 2.6 p = 0.01	t = 1.9 p = 0.03	t = 2.1 p = 0.03
3 months later	l.e.	t = 2.6 p < 0.01	t = 2.9 p < 0.01	t = 1.9 p = 0.05	t = 0.6 p > 0.05	t = 0.9 p > 0.05
	r.e.	t = 2.0 p = 0.04	t = 3.9 p < 0.01	t = 1.9 p = 0.05	t = 2.1 p = 0.03	t = 1.8 p > 0.05
6 months later	l.e.	t = 1.0 p > 0.05	t = 1.5 p > 0.05	t = 0.1 p > 0.05	t = 0.05 p > 0.05	t = 0.5 p > 0.05
	r.e.	t = 0.4 p > 0.05	t = 1.7 p > 0.05	t = 0.7 p > 0.05	t = 1.1 p > 0.05	t = 0.4 p > 0.05

l.e. = left eye; r.e. = right eye.

identical for both groups, the control group also had 5 min of interrupted breathing from a system SAA-1.

A complete ophthalmological examination, including a visual field test by the Goldmann method, was performed 2 to 10 days after treatment, and then 3 and 6 months after treatment by HBO.

Statistical analysis used arithmetic mean, standard error, standard deviation, and sampling distribution. Sampling distribution was done with the Student's *t*-test. Findings with an error probability value of < 0.05 were considered to be statistically significant.

Results

The value of IOP after HBO did not change significantly in either the experimental or control group (Table 1).

The visual field results of the subjects from the experimental group before and after treatment are shown in Table 2, and results of Student's *t*-test in Table 3.

A significant reduction of the blind spot and an enlargement of the area inside isopters after HBO were confirmed in the subjects in the experimental group ($p < 0.05$).

Reexaminations after 3 months showed further detaining-significant changes in the subjects in the experimental group ($p < 0.05$), except for the I₃ and I₄ isopters of the left eye and I₄ isopter of the right eye.

After 6 months, reexamination of the visual field showed no significant difference between the experimental and control group ($p > 0.05$).

The diagrams of the mean values (mean \pm SE) for the blind spot and isopters before and after treatment, after 3 and 6 months are shown in Figs. 1 and 2.

Within the control group there were no statistically significant changes in the visual field ($p > 0.05$) - Table 4.

The visual acuity did not change in subjects in either group.

Discussion

An increase in the partial pressure of the oxygen in the lungs in hyperbaric oxygen breathing results in an increased uptake of oxygen in the arterial blood in a physically dissolved form (Jain 1990). This increase in oxygen content in the blood can compensate for a decrease in the blood flow in ischemic areas (Mathieu 1992). Besides delivering additional

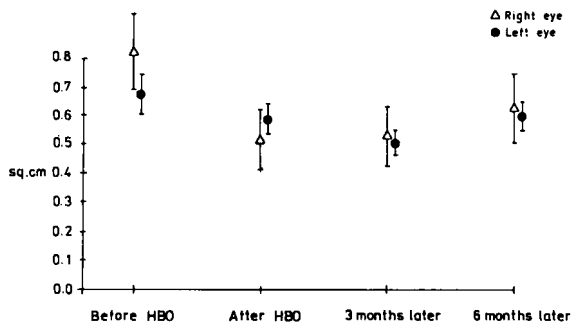


Fig. 1.

By HBO significantly reduced blind spot area remained stable for 3 months.

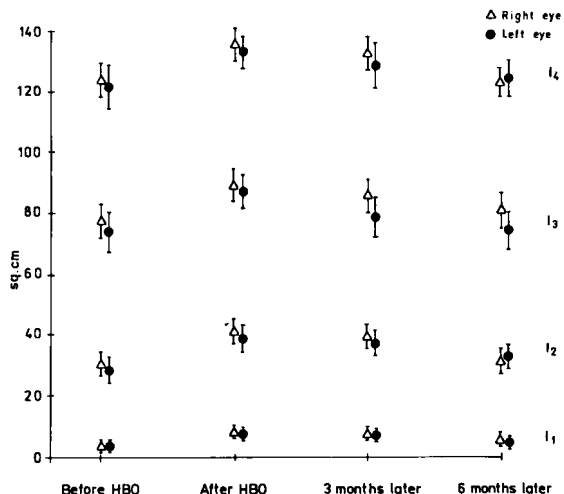


Fig. 2.

By HBO significantly improved visual field remained stable for 3 months, except l.e. I₃, and I₄.

amounts of physically dissolved oxygen to the tissue, HBO acts antiedematously and stimulates formation of collagen (Nylander et al. 1983).

The usefulness of HBO in treating retinal ischemia is supported by Jampol (1987), who when using HBO, found an increased pO₂ in the preretinal part of the vitreous body.

In treatment of 13 patients with glaucoma, Andreev et al. (1978), using HBO, found improvement of visual acuity and visual fields in about half of the patients. Unfortunately, they did not make detailed numerical data of their experiments, thereby enabling us to compare results.

Our study showed a significant reduction (p < 0.05) of the blind spot in the subjects in the experimental group after HBO and again 3 months later. A reduced retinal light sensitivity, manifested as a reduction of the outer isopters, had im-

proved significantly after HBO and 3 months later (p < 0.05), except for I₃ and I₄ isopters of the left eye and I₄ isopter of the right eye (p > 0.05). Unfortunately, we have not the technical means to employ computerized perimetry for visual field assessment, which would be better.

The beneficial effects of HBO on visual fields are probably achieved by the increase in the distribution of oxygen dissolved per volume unit of blood circulating through regions suffering from hypooxygenation. The effects of HBO are more pronounced in hypoxic tissue and vasoconstriction doesn't take place in the hypoxic tissue. HBO im-

Table 4.

Visual fields of the control group before and after hyperbaric normoxic treatment (mean ± SE). No significant improvement was found in the control group after hyperbaric normoxic treatment.

		Blind spot	Isopters			
			I ₁	I ₂	I ₃	I ₄
Surface in cm ² before treatment	l.e.	0.78 ± 0.08*	3.94 ± 0.9*	28.0 ± 2.5*	72.5 ± 4.9*	122.7 ± 3.8*
	r.e.	0.71 ± 0.04*	4.8 ± 0.7*	31.1 ± 3.3*	76.2 ± 4.8*	124.0 ± 5.3*
Surface in cm ² after treatment	l.e.	0.82 ± 0.08*	3.87 ± 0.8*	27.7 ± 2.4*	71.2 ± 4.9*	122.6 ± 3.6*
	r.e.	0.72 ± 0.05*	4.9 ± 0.7*	31 ± 3.2*	76.5 ± 4.7*	119.0 ± 7.7*

* p < 0.05; l.e. = left eye; r.e. = right eye.

proves the elasticity of the red blood cells and reduces platelet aggregation (Jain 1990; Mathieu 1992). Combined with the ability of the plasma to carry dissolved oxygen to areas red blood cells cannot reach, we presume that HBO has a beneficial effect on the oxygenation of the optic nerve head and adjacent retinal structures. These beneficial effects of HBO slowly decrease and after 6 months there is no significant effect on visual field.

Our study indirectly points to the role of a vascular mechanism in the pathogenesis of glaucoma. It is quite possible that the disturbed light sensitivity of eye tissue in the region of capillary hypoperfusion is only of a functional nature and because of that reacts agreeably to HBO.

No changes in visual fields were found in subjects in the control group. This suggests that hyperbaric treatment alone without hyperoxygenation has no effect on the visual fields of glaucoma patients.

We found that HBO had no effect on IOP, which agrees with the findings of Lyne (1978). On the other hand, Gallin (1978) found a drop of IOP by HBO.

Acknowledgments

Presented in part at The Joint Meeting of 2nd Swiss Symposium on Hyperbaric Medicine held in Basel, 1988.

References

- Anderson D R (1977): Is ischemia the villain in glaucomatous cupping and atrophy? In: Brochurst R J, Boruchoff S A, Hutchinson B T & Lessell S (eds). *Controversy in Ophthalmology*, p 312. W B Saunders, Philadelphia.
- Andreev G N et al. (1978): The usage of individual clinical system on hyperbaric oxygenation in a complex treatment of some eye diseases. *Ophthalmol Zh* 33(3): 191-195.
- Cramer S (1985): Care of the injured soldier; A medical readiness role for clinical hyperbaric oxygen therapy. *Mil Med* 150: 372-375.

- Duke-Elder S & Barric I (1976): *Glaucoma and hypotony*. In: Duke-Elder S (ed). *System of ophthalmology. Diseases of lens and vitreus. Glaucoma and hypotony*, vol XI, p 379-391. Henry Kimpton, London.
- Gallin P, Pados S & Iablonski M (1978): The effect of increased oxygen on intraocular pressure of human eyes. *Invest Ophthalmol Vis Sci (Suppl)* 31: 144-151.
- Greve E L (1989): The effect of treatment on progression of glaucoma (Summary). *Surv Ophthalmol (Suppl)* 33: 431-433.
- Hayreh S S, Revie H S & Edwards J (1970): Vasogenic origin of visual fields defects and optic nerve change in glaucoma. *Br J Ophthalmol* 54(7): 461-472.
- Jain K K (1990): *Textbook of hyperbaric medicine. Hyperbaric oxygenation and ophthalmology*, p 377. Hogrefe and Huber Publishers, Toronto - Lewiston NY - Bern - Gotingen - Stuttgart.
- Jampol L M (1987): Oxygen therapy and intraocular oxygenation. *Trans Am Ophthalmol Soc* 91: 407-417.
- Lyne H J (1978): Ocular effects of hyperbaric oxygen. *Trans Ophthalmol Soc UK* 98: 66-68.
- Mathieu D et al. (1992): Non invasive assessment of vasoconstrictive effects of hyperoxygenation in focal ischemia. In: Schmutz J & Wendling J (eds). *Proceedings of Joint Meeting on Diving and Hyperbaric Medicine*, p 55-57. Foundation for hyperbaric medicine, Basel.
- Nylander G et al. (1983): Reduction of postischemic edema with hyperbaric oxygen. *Plast Reconstr Surg* 76: 596-601.
- Phelps C D (1972): The pathogenesis of optic nerve damage in glaucoma. A review of the vascular hypothesis. In: Blodi F (ed). *Current concepts in ophthalmology*, p 142. C V Mosby, St Louis.
- Quigley A H et al. (1981): Optic nerve damage in human glaucoma. *Arch Ophthalmol* 99: 635-649.
- Radius R L (1987): Anatomy of the optic nerve head and glaucomatous optic nerve head neuropathy. *Surv Ophthalmol* 32(1): 35-44.
- Tuulonen A & Airaksinen P J (1991): Initial glaucomatous optic disc and retinal nerve fiber layer abnormalities and their progression. *Am J Ophthalmol* 111: 485-490.

Received on May 21st, 1992.

Author's address:
 Lovre Bojić,
 Starčevićeva 26,
 HR-58000 Split,
 Croatia.